

AKT Example Questions

(January 2019)

1. Low mood

A 50-year-old woman is taking methotrexate 15 mg once weekly for rheumatoid arthritis. She has developed low mood, poor sleep pattern and early morning wakening.

She wishes to try medication as her symptoms are affecting her ability to work.

Which is the SINGLE MOST appropriate medication? Select ONE option only.

- A. Amitriptyline
- B. Citalopram
- C. Lofepramine
- D. Mirtazapine
- E. Venlafaxine

Answer: B (Citalopram)

SSRIs are safer than tricyclic antidepressants and are the first choice in the treatment of depression due to a lower incidence of side effects and safer in overdose.

NICE guidance *Depression in adults with a chronic physical health problem: recognition and management [CG91]* suggests citalopram or sertraline first-line because they have less propensity for interactions.

[Content Guide reference: Mental health problems](#)
[Curriculum: 3.10 Care of people with mental health problems](#)

2. Weakness

A 35-year-old woman has noticed increasing weakness and numbness in her legs and arms over the past few days. Today she is feeling short of breath on exertion.

Six weeks ago she had diarrhoea. Stool culture confirmed infection with *Campylobacter jejuni*. She was treated with ciprofloxacin and recovered fully.

Which is the SINGLE MOST likely diagnosis? Select ONE option only.

- A. Drug-induced neuropathy
- B. Guillain-Barré syndrome
- C. Multiple sclerosis
- D. Myasthenia gravis
- E. Transverse myelitis

Answer B. (Guillain-Barré syndrome)

Guillain-Barré syndrome is an acute ascending polyneuropathy which usually occurs following an infection. It can eventually affect the respiratory muscles

[Content Guide reference: Neurological](#)

[Curriculum: 3.18 Care of people with neurological problems](#)

3. Emergency contraception

A 26-year-old woman is on day 14 of a 28-day cycle and had unprotected sexual intercourse 12 hours ago. This was the first occasion within this cycle.

She requests levonorgestrel 1.5 mg emergency contraception but also wants to quick-start the combined hormonal contraceptive pill (CHC).

Having started the CHC, which is the SINGLE MOST appropriate length of time that she needs to take EXTRA contraceptive precautions, if any? Select ONE option only.

- A. 24 hours
- B. 5 days
- C. 7 days
- D. 14 days
- E. No additional precautions needed

Answer C. (7 days)

The rules for quick start contraception are clearly outlined in the 2017 Faculty of Sexual Health and Reproductive Healthcare guidance, but vary depending on the type of emergency contraception and the subsequent contraceptive choice.

The AKT regularly tests understanding of contraception and this area remains difficult for many candidates. If this is an area you find difficult, it would be worth addressing this as a learning need in your training.

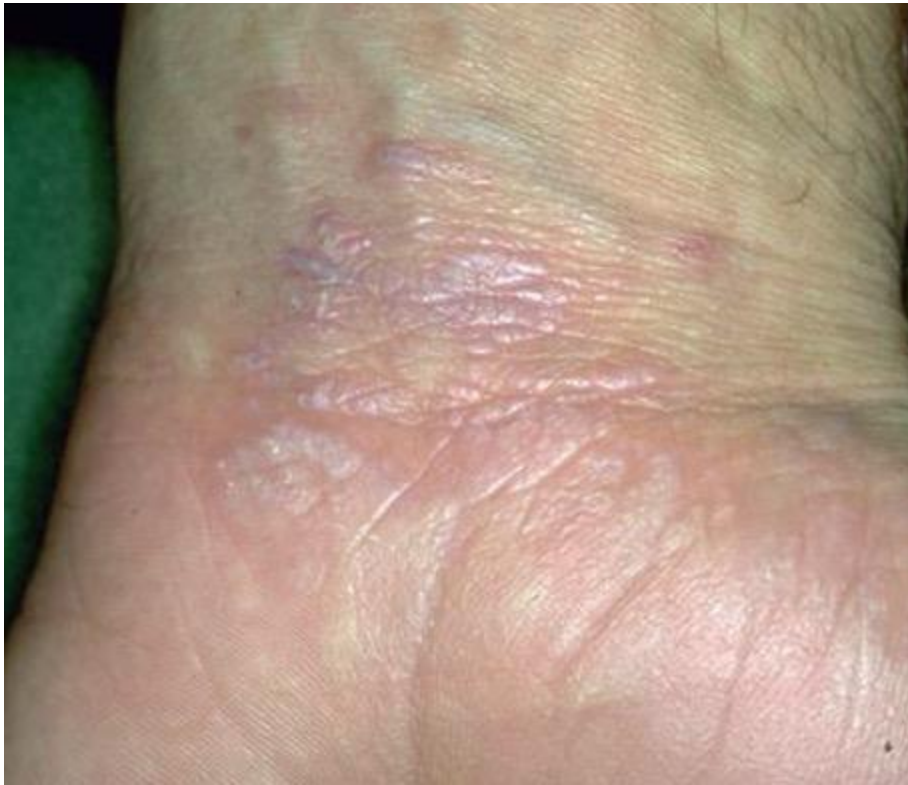Reference: Quick Starting Contraception. FSRH Guideline 2017

[Content Guide reference: Women's health and Sexual health](#)
[Curriculum: 3.06 Women's health](#)

4. Skin rash

A 45-year-old man has had an intensely itchy rash on his wrists for the past three weeks. The appearance of the rash is as shown.

Which is the **SINGLE MOST** appropriate **FIRST-LINE** treatment? **Select ONE** option only.



©Dermis.net

- A. Betamethasone 0.1% ointment
- B. Calcipotriol cream
- C. Fusidic acid ointment
- D. Permethrin cream
- E. Pimecrolimus 1% cream

Answer A. (Betamethasone 0.1% ointment)

This is the typical appearance of lichen planus. Potent steroids are first-line treatment.

[Content Guide reference: Skin problems](#)

[Curriculum: 3.21 Care of people with skin problems](#)

5. Hearing loss

A 46-year-old man developed sudden loss of hearing in his right ear six weeks ago. His hearing has not improved at all. He has had no other symptoms and is otherwise well.

Examination of the ear canals and tympanic membranes is normal. A private hearing assessment clinic has confirmed 90% sensorineural hearing loss on the right side.

Which is the SINGLE MOST likely diagnosis? Select ONE option only.

- A. Cholesteatoma
- B. Idiopathic
- C. Otosclerosis
- D. Psychosomatic
- E. Ramsey-Hunt syndrome

Answer B. (Idiopathic)

It is important to recognise idiopathic unilateral sudden sensorineural hearing loss, because if the patient is assessed within three weeks of onset - unlike this man - treatment with oral steroids may be beneficial.

[Content Guide reference: ENT problems](#)

[Curriculum: 3.15 Care of People with ENT, Oral and Facial Problems](#)

6. Lethargy

A 50-year-old man has become increasingly tired and lethargic over the past six months and has developed erectile dysfunction. His wife comments that he looks tanned even in the winter months.

His blood results are as follows:

		Normal range
Haemoglobin (g/L)	140	
Ferritin ($\mu\text{g/L}$)	1200	30-300
Transferrin saturation (%)	84	15-45%

Which is the SINGLE MOST likely diagnosis? Select ONE option only.

- A. Addison's disease
- B. Chronic active hepatitis
- C. Haemochromatosis
- D. Hypothyroidism
- E. Type 2 diabetes

Answer C. (Haemochromatosis)

Haemochromatosis is an inherited disorder which increases absorption of dietary iron. This accumulates gradually in the liver, pancreas, skin, joints, heart or endocrine glands causing serious tissue damage and is associated with erectile dysfunction. Ferritin and transferrin are raised.

[Content Guide reference: Metabolic and endocrine problems](#)
[Curriculum: 3.17 Care of people with metabolic problems](#)

Respiratory pathogens

A	Adenovirus	E	Measles virus
B	Epstein-Barr virus	F	<i>Mycoplasma pneumoniae</i>
C	<i>Group A beta-haemolytic streptococcus</i>	G	Respiratory syncytial virus
D	<i>Legionella pneumophila</i>	H	<i>Streptococcus pneumoniae</i>

For each patient, select the **SINGLE MOST** likely **CAUSATIVE** agent from the list of options.

7. A 10-month-old girl has had a fever and rhinitis for two days followed by a persistent cough. She has a temperature of 38 °C, respiratory rate over 40/min and fine crackles throughout both lungs.

Answer G. (Respiratory syncytial virus)

This child has bronchiolitis. Diagnosis is based on the presence of coryzal prodromal symptoms lasting one to three days, followed by persistent cough
AND either tachypnoea or chest recession (or both)
AND either wheeze or crackles on chest auscultation (or both)

Reference: Bronchiolitis in children: diagnosis and management NICE guideline (NG) 9, 2015 www.nice.org.uk/guidance/ng9

Content Guide reference: Respiratory problems and Children and young people
Curriculum: 3.03 Care of acutely ill people

8. A 15-year-old boy is treated with amoxicillin for a purulent sore throat and high fever. 48 hours later, he develops a widespread, non-blanching maculopapular rash.

Answer B. (Epstein-Barr virus)

Amoxicillin and ampicillin can cause severe, generalised rash in adolescents and young adults with glandular fever due to acute Epstein-Barr virus infection.

Content Guide reference: Respiratory problems and Pharmacotherapeutics
Curriculum: 3.03 Care of acutely ill people

9. Risk of hip fracture

A cohort study evaluated the relationship between dietary calcium supplementation and hip fractures in post-menopausal women. 100 women took calcium supplements and 100 women took placebo tablets.

Over the three-year period, five women had hip fractures in the calcium group and ten women had hip fractures in the placebo group.

What is the RISK of a hip fracture in the TREATED group? Select ONE option only.

- A. 0.01
- B. 0.05
- C. 0.1
- D. 0.5
- E. 1.0

Answer B. (0.05)

Five women out of 100 had a hip fracture when taking calcium supplements i.e. $5/100=0.05$

Any calculations in the AKT are arithmetically very simple and are included so that candidates can demonstrate their understanding of statistical terms and measures. An on-screen calculator is included in the live exam for candidates to use if they wish.

[Content Guide reference: Research, statistics and epidemiology](#)
[Curriculum: 2.04 Enhancing Professional Knowledge](#)

10. Drug dose calculation

A three-year-old girl has recurrent urinary tract infections and the paediatrician has recommended trimethoprim prophylaxis at a dose of 2 mg/kg at night.

She weighs 12.5 kg and trimethoprim suspension is available as 50 mg/5mls.

What VOLUME of suspension (in mls) should the child's mother give her every evening?

Type your answer in the following text box. Use figures NOT words. Percentages and fractions are NOT acceptable.

 mls

Answer 2.5 mls

Drug calculations are common and important, and will be tested in every AKT. The information given makes the calculation straightforward and a calculator is not necessary - although it is provided.

This child weighs 12.5 kg and the dose is 2 mg per kilogram, so she needs a once daily dose of 25 mg. If trimethoprim suspension contains 50 mg in 5 mls it will contain 25 mg in 2.5 mls.

[Content Guide reference: Pharmaco-therapeutics](#)
[Curriculum: 2.02 Patient Safety and Quality of Care](#)

Side effects of rheumatological drugs

- A. Alendronic acid
- B. Allopurinol
- C. Diclofenac
- D. Etoricoxib
- E. Febuxostat
- F. Hydroxychloroquine
- G. Infliximab
- H. Methotrexate

For each drug side effect, select the SINGLE MOST likely causative drug. Select ONE option only.

11. Retinopathy

Answer F. (Hydroxychloroquine)

Although retinopathy is rare, people taking long-term hydroxychloroquine should have an annual vision check.

[Content Guide reference: Musculo-skeletal problems and Pharmacotherapeutics Curriculum: 2.02 Patient Safety and Quality of Care](#)

12. Pneumonitis

Answer H. (Methotrexate)

Lung disease is a well-recognised manifestation of rheumatoid arthritis, including pulmonary nodules and pleural effusions. Methotrexate-induced pneumonitis is a rare but life-threatening adverse drug reaction.

[Content Guide reference: Musculo-skeletal problems and Pharmacotherapeutics Curriculum: 2.02 Patient Safety and Quality of Care](#)

13. Visual disturbance

A 63-year-old man with hypertension suddenly loses the vision in his left eye. Visual acuity is hand movements only on the left and 6/6 on the right.

Fundoscopy of the left eye shows flame-shaped retinal haemorrhages spreading out from the disc.

Which is the SINGLE MOST likely diagnosis? Select ONE option only.

- A. Acute glaucoma
- B. Central retinal artery occlusion
- C. Central retinal vein occlusion
- D. Retinal detachment
- E. Vitreous haemorrhage

Answer C. (Central retinal vein occlusion)

The history and clinical findings are typical of central retinal vein occlusion, with hypertension as the underlying risk factor.

[Content Guide reference: Eye problems](#)
[Curriculum: 3.16 Care of People with Eye Problems](#)

14. Family history of diabetes

A 47-year-old woman has a screening blood test because of her family history of type 2 diabetes. Her BMI is 29 kg/m². She feels well.

Her blood test result is as follows:

HbA_{1c} 40 mmol/mol

Which is the SINGLE MOST appropriate interpretation of the result? Select ONE option only.

- A. Impaired fasting glycaemia
- B. Impaired glucose tolerance
- C. Normal
- D. Prediabetes
- E. Type 2 diabetes

Answer C. (Normal)

This woman has an HbA_{1c} at the upper limit of the WHO normal range. The AKT tests understanding of diagnostic threshold values. NICE and SIGN guidelines, as well as the RCGP eLearning website, are frequently used reference sources.

[Content Guide reference: Metabolic and endocrine problems](#)
[Curriculum: 3.17 Care of People with Metabolic Problems](#)

15. Child development

Specialist referral is **MOST APPROPRIATE** for which **TWO** of the following children?
Select **TWO** options only.

- A. A four-week-old boy whose mother reports he does not smile
- B. A four-month-old girl who cannot grasp an object when it is placed in her hand
- C. A four-month-old boy who cannot sit unsupported
- D. A two-year-old girl who cannot go down stairs with one foot per step
- E. A two-year-old girl who cannot hop
- F. A three-year-old boy who cannot combine words into a simple sentence

Answers

- B. (A four-month-old girl who cannot grasp an object when it is placed in...)
- F. (A three-year-old boy who cannot combine words into a simple sentence)

This question highlights the need for an understanding of normal and delayed child development.

Although GPs in training may not have much experience of key childhood developmental milestones, awareness of these is an essential part of being a GP.

The exam board have regularly fed back to candidates that this is an area that will continue to be tested.

This is an example of multiple best answer question, where more than one correct answer has to be correct to score one mark. If you attempt to move on after marking only one answer, there is a screen warning to prompt you to look again.

[Content Guide reference: Children and young people](#)
[Curriculum: 3.04 Care of Children and Young People](#)

16. Disclosure of medical information

A 32-year-old man with alcohol dependence requests a medical report to support his application for rehousing by the local authority. The local authority rejects the application and he now wants to see a copy of the medical report.

In which TWO of the following situations is it MOST appropriate to DENY disclosure? Select TWO options only.

- A. It may result in a complaint to the practice.
- B. It may reveal information about another patient.
- C. It may upset the patient.
- D. The GP who wrote the report may come to serious harm.
- E. The local authority has not agreed to the disclosure.
- F. The report contains factually incorrect information

Answers

- B. (It may reveal information about another patient)
- D. (The GP who wrote the report may come to serious harm)

This issue is covered in more detail in GMC Confidentiality - good practice in handling patient information (2017).

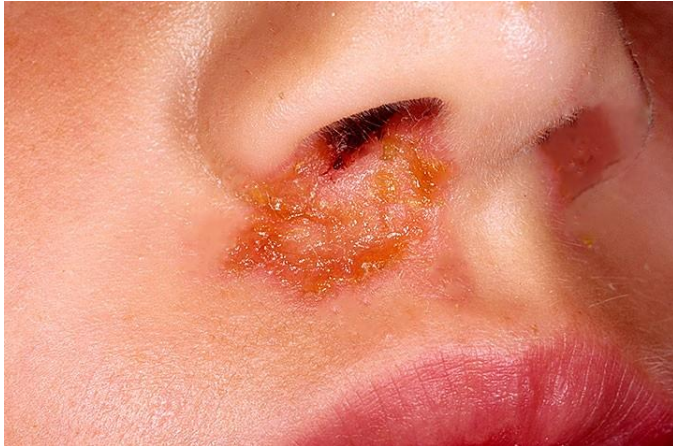If asked to provide information to third parties you should:

- be satisfied that the patient has sufficient information
- obtain written consent but if a patient refuses consent, or if it is not practicable to get their consent, information can still be disclosed if it is required by law or can be justified in the public interest
- only disclose relevant factual information you can substantiate
- offer to show your patient a copy of any report you write, unless:
 - (i) they have already indicated they do not wish to see it
 - (ii) disclosure would be likely to cause serious harm
 - (iii) disclosure would be likely to reveal information about another person who does not consent

Content Guide reference: Administration, ethical and regulatory frameworks
Curriculum: 2.03 The GP in the Wider Professional Environment

17. Skin infections in children

An eight-year-old child has had a localised rash around the nose for two days.



According to current national guidance, which is the SINGLE MOST appropriate MINIMUM number of days that this child be kept away from school once treatment has started? Select ONE option only.

- A. 1
- B. 2
- C. 3
- D. 5
- E. 7

Answer B. (2 days)

This child has impetigo. Once treatment starts the earliest a child can return to school is 2 days provided there is a good response to treatment. Practical knowledge of incubation and quarantine periods will be required and is frequently asked by parents.

[Content Guide reference: Infectious diseases](#)
[Curriculum: 3.04 Care of Children and Young People](#)

18. Liver disease

A 28-year-old man had a flu-like illness with anorexia, nausea and fever while on holiday in Thailand last week. When he was seen yesterday, he was jaundiced but abdominal and general examinations were otherwise normal.

His liver function tests are as follows:

		Normal range
Bilirubin ($\mu\text{mol/L}$)	98	< 21
Aspartate aminotransferase (AST) (IU/L)	228	< 40
Alanine aminotransferase (ALT) (IU/L)	186	< 40
Alkaline phosphatase (IU/L)	302	35 – 104
Albumin (g/L)	35	35 – 50
Total protein (g/L)	73	60 – 80

Which is the SINGLE MOST appropriate SPECIFIC DIAGNOSTIC test for this patient? Select ONE option only.

- A. Anti-nuclear antibodies
- B. Blood alcohol level
- C. Hepatitis A IgM
- D. Hepatitis B IgG
- E. HIV

Answer C. (Hepatitis A IgM)

This man is likely to have hepatitis A. The correct diagnostic test is IgM for recent infection rather than IgG for past infection. Although primary HIV infection could present with a similar clinical picture, HIV seroconversion is likely to occur 2-4 weeks after exposure and testing now could be too early.

[Content Guide reference: Infectious diseases](#)
[Curriculum: 3.13 Digestive Health](#)

Risk assessment tools

- A. ABCD²
- B. CHA₂DS₂-VASc
- C. FRAX
- D. Qcancer
- E. QRisk2
- F. Wells score
- G. No appropriate risk tool available

For each patient described, select the SINGLE MOST appropriate risk assessment tool, if any, from the list of options.

19. A 54-year-old man is diagnosed with atrial fibrillation. His blood pressure is 150/60, pulse is 75/min and irregular and his heart sounds are normal.

Answer B. (CHA₂DS₂-VASc)

The ABCD² score was previously used to quantify stroke risk after TIA but guidance has recently changed. CHA₂DS₂-VASc assesses risk of stroke in atrial fibrillation. QRisk2 is used to assess cardiovascular risk for primary prevention. FRAX is used to calculate 10-year risk of fracture.

[Content Guide reference: Cardiovascular problems](#)
[Curriculum: 3.12 Cardiovascular Health](#)

20. A 58-year-old woman with breast cancer has chest pain and shortness of breath. Her pulse is 98/min and regular and her heart sounds are normal.

Answer F. Wells score

There are two Wells assessment tools, one for pulmonary embolism and one for deep vein thrombosis.

[Content Guide reference: Cardiovascular problems](#)
[Curriculum: 3.12 Cardiovascular Health](#)

21. Medical standards of fitness to drive

A 65-year-old retired man had an elective coronary artery angioplasty and stent insertion one week ago. He is now well and asymptomatic. He asks you for advice about driving his car.

According to DVLA guidance, which is the SINGLE MOST appropriate advice? Select ONE option only.

- A. He may resume driving immediately
- B. He may resume driving after a further week
- C. He may resume driving one month after the angioplasty
- D. He may resume driving six months after the angioplasty
- E. He must inform the DVLA and await their decision before resuming driving

Answer A. (He may resume driving immediately)

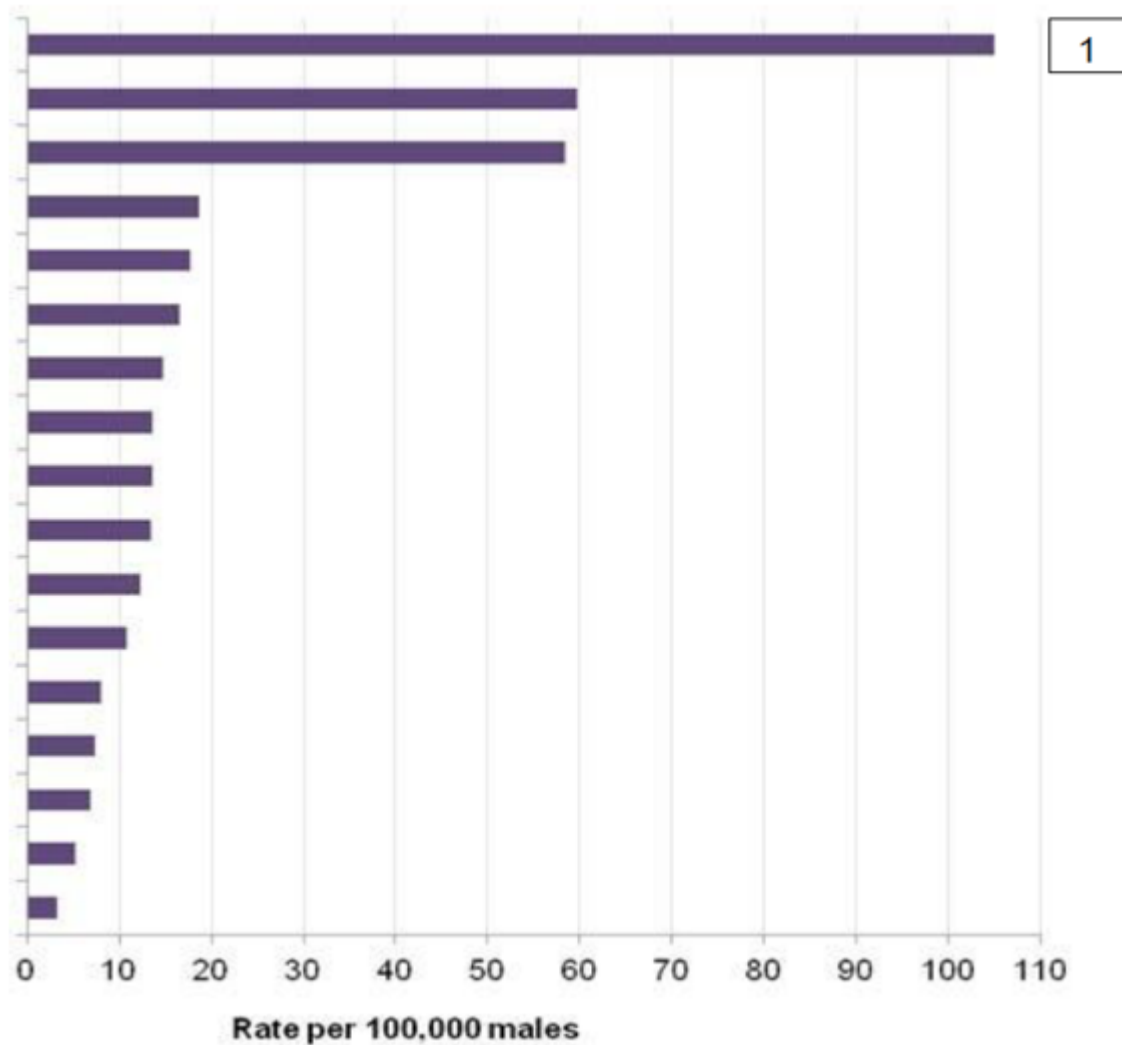
DVLA guidance is to stop driving for one week after the procedure. Candidates are not expected to know all the guidance for all medical conditions but it is important to be aware of common restrictions and legal requirements.

Remember there is a difference in guidance between car drivers, and goods and public service vehicle drivers.

[Content Guide reference: Administration, ethical and regulatory frameworks](#)
[Curriculum: 2.2 Patient Safety and Quality of Care](#)

22. Data interpretation

The following graph shows age-standardised **INCIDENCE** rates for common cancers in males in the United Kingdom (2008 – 2010).



Which **SINGLE** cancer is represented by the bar labelled '1'? Select **ONE** option only.

- A. Bladder
- B. Colorectal
- C. Lung
- D. Non-Hodgkin's lymphoma
- E. Prostate

Answer E. (Prostate)

It is important to know about the epidemiology of common cancer, including an understanding of terms such as incidence, prevalence and mortality rates.

Research and statistics questions in the AKT are designed to test an understanding of data and different ways that they may be presented and interpreted.

[Content Guide reference: Research, statistics and epidemiology](#)
[Curriculum: 2.04 Enhancing Professional Knowledge](#)

23. Management of dyspepsia

A 43-year-old woman with persistent dyspepsia for six weeks has a positive *H. pylori* stool antigen result. She is treated with a one-week course of triple therapy. She is reviewed four weeks later and is symptom free.

Which is the SINGLE MOST appropriate NEXT management option? Select ONE option only.

- A. Check eradication with *H. pylori* stool antigen test
- B. Check eradication with *H. pylori* breath test
- C. Continue proton-pump inhibitor therapy for a further four weeks
- D. Maintenance low-dose proton-pump inhibitor therapy long term
- E. No further treatment necessary

Answer E. (No further treatment necessary)

Current guidance is that no follow-up is required after triple therapy if the patient is symptom free.

[Content Guide reference: Digestive problems including nutrition](#)
[Curriculum: 3.13 Digestive Health](#)

24. The investigation of failure to conceive

A 25-year-old woman has failed to conceive for three years. She has had recurrent pelvic pain due to endometriosis. Investigations in primary care are as follows:

Full blood count	normal
Thyroid function	normal
Sex hormone profile	normal
Rubella serology	immune
Day 21 progesterone	normal
<i>Chlamydia</i> swab	negative
Pelvic ultrasound	normal

Her partner's semen analysis is reported as normal.

A referral to secondary care is agreed and she asks what is likely to happen next.

According to current guidance, which is the SINGLE MOST appropriate NEXT investigation? Select ONE option only.

- A. CT scan pelvis
- B. Hysterosalpingogram
- C. Hysteroscopy
- D. Laparoscopy
- E. Post-coital test

Answer D. (Laparoscopy)

Candidates are not expected to know detailed secondary care investigation pathways, but should be able to help patients understand what is most likely to happen following a referral/admission. Laparoscopy would enable assessment of the extent of her endometriosis and guide any further intervention that may be required.

[Content Guide reference: Women's health](#)
[Curriculum: 3.6 Women's Health](#)

25. Asthma

An 18-year-old woman with asthma has become increasingly wheezy over the past two days. She is unable to complete a sentence in one breath. Examination findings are as follows:

Heart rate	115/min	
Respiratory rate	30/min	
Peak flow	200 L/min	Predicted 450 L/min

According to current guidance, which is the SINGLE MOST appropriate description of the SEVERITY of her asthma? Select ONE option only.

- A. Mild
- B. Moderate
- C. Severe
- D. Life-threatening
- E. Near-fatal

Answer C. (Severe)

Current SIGN/BTS guidance on asthma (2016) defines an acute severe asthma attack as follows:

Any one of:

- PEF 33–50% best or predicted
- Respiratory rate ≥ 25 /min
- Heart rate ≥ 110 /min
- Inability to complete sentences in one breath

[Content Guide reference: Respiratory problems](#)
[Curriculum: 3.19 Respiratory Health](#)

26. Thyroid treatment

A 70-year-old woman with hypothyroidism has been taking levothyroxine 100 mcg daily for the past 30 years. She has had infrequent thyroid function monitoring over that period.

Her TSH level six years ago was 0.3 mU/L and currently it is <0.01 mU/L.

Which SINGLE condition is she MOST at risk of developing? Select ONE option only.

- A. Hyperparathyroidism
- B. Ischaemic heart disease
- C. Osteopetrosis
- D. Osteoporosis
- E. Paget's disease

Answer D. (Osteoporosis)

A patient on replacement levothyroxine should be monitored regularly to ensure the dose is correct. Over-replacement is associated with osteoporosis, which is the most likely risk to this woman.

[Content Guide reference: Musculo-skeletal problems including trauma](#)
[Curriculum: 3.20 Care of People with Musculoskeletal Problems](#)

27. Injectable contraception with depot medroxyprogesterone acetate (DMPA)

According to UKMEC 2016 guidance, for which **ONE** of the following conditions are the the risks of DMPA **MOST** likely to outweigh the advantages? Select **ONE** option only.

- A. Breast cancer
- B. Current smoker
- C. Diabetes mellitus
- D. Previous ovarian cysts
- E. Previous ectopic pregnancy

Answer A. (Breast cancer)

DMPA should not be used within five years of a diagnosis of breast cancer and, even after that, should only be used if non-hormonal methods are unacceptable and there is no evidence of disease recurrence.

Because parental progestogen contraceptives inhibit ovulation, they are protective against ovarian cysts and ectopic pregnancy.

[Content Guide reference: Women's health](#)
[Curriculum: 3.6 Women's Health](#)

28. Child growth

A two-month-old girl arrived with her family from Ireland six months ago. She had not seen a health worker and had no immunisations prior to arriving in the UK.

Her routine measurements have fallen from the 50th to below the 25th centile growth line over the past three months. She has a history of minor respiratory infections and recurrent gastroenteritis.

Which is the SINGLE MOST appropriate DIAGNOSTIC investigation? Select ONE option only.

- A. Chromosome analysis
- B. Glucose-6-phosphate dehydrogenase level
- C. Jejunal biopsy
- D. Sweat test
- E. Thyroid function test

Answer D. (Sweat test)

The sweat test measures the concentration of chloride excreted in sweat and is used to test for cystic fibrosis – which is the most likely of the given diagnoses. Both the UK and Ireland's newborn screening programmes include cystic fibrosis in the heel prick test, but it is important to remember that some children will have missed routine screening and immunisations.

All the AKT question formats, apart from the free text, require the candidate to identify the best answer(s) from a given list of plausible alternatives, using all of the information in the question. There may be other answers which are not included in the option list, but you have to focus on the best available answer for the specific question asked.

[Content Guide reference: Children and young people](#)
[Curriculum: 3.4 Care of Children and Young people](#)

29. Childhood illness

A seven-year-old girl has a fever associated with a sore throat and loss of appetite. She has small red ulcers in her mouth and itchy spots on the palms of her hands and soles of her feet.

Which is the SINGLE MOST likely virus causing her symptoms? Select ONE option only.

- A. Coxsackie A
- B. Herpes simplex
- C. Measles
- D. Parvovirus B19
- E. Varicella-zoster

Answer A. (Coxsackie A)

This child has hand, foot and mouth disease which is caused by various strains of coxsackie virus (usually A) or enterovirus.

[Content Guide reference: Children and young people and Infectious diseases](#)
[Curriculum: 3.4 Care of Children and Young people](#)

30. Tiredness

A 50-year-old woman, who has recently been diagnosed with hypertension, has painful knees. She feels tired and her memory is poor. She has lost her appetite, feels nauseated and is constipated. Urinalysis is normal.

Which is the SINGLE MOST likely diagnosis? Select ONE option only.

- A. Addison's disease
- B. Chronic renal failure
- C. Conn's syndrome
- D. Cushing's syndrome
- E. Hyperparathyroidism

Answer E. (Hyperparathyroidism)

The patient is most likely to have hyperparathyroidism. This is associated with secondary hypertension and she has symptoms due to hypercalcaemia - such as bone and joint pain, loss of appetite, nausea, tiredness and psychological symptoms.

[Content Guide reference: Metabolic and endocrine problems](#)
[Curriculum: 3.17 Care of People with Metabolic Problems](#)

31. Anal pain

For the past week, a 30-year-old woman has noticed fresh red blood on the toilet paper and experiences sharp pain around the anus when she defecates. Today she can feel a very tender lump at the anal margin.

Which is the SINGLE MOST likely diagnosis? Select ONE option only.

- A. Anal fissure
- B. Anorectal abscess
- C. Crohn's disease
- D. Pilonidal abscess
- E. Thrombosed haemorrhoid

Answer E. (Thrombosed haemorrhoid)

The history is suggestive of a thrombosed haemorrhoid. Sharp pain without a lump would more likely to be from an anal fissure.

[Content Guide reference: Digestive problems including nutrition](#)
[Curriculum: 3.13 Digestive Health](#)

Visual problems

- A. Berry aneurysm
- B. Cerebral glioma
- C. Drug-induced
- D. Graves' disease
- E. Guillain-Barré syndrome
- F. Idiopathic intracranial hypertension
- G. Multiple sclerosis
- H. Myasthenia gravis
- I. Optic neuritis
- J. Pituitary adenoma
- K. Stroke

For each patient described, select the SINGLE MOST likely diagnosis from the list of options.

32. A 27-year-old woman has severe daily headaches which she describes as pulsatile. Her blood pressure is 130/75 and her BMI is 34 kg/m². She has bilateral papilloedema.

Answer F. (Idiopathic intracranial hypertension)

Idiopathic intracranial hypertension (IIH) occurs mainly in overweight women. Symptoms are related to raised intracranial pressure and field loss is common.

[Content Guide reference: Eye problems](#)
[Curriculum: 3.16 Care of People with Eye Problems](#)

33. A 22-year-old woman has had amenorrhoea for the last four months. She has also been having intermittent headaches but is otherwise well. Confrontational visual field testing shows bilateral temporal hemianopia. Pregnancy test is negative.

Answer J. (Pituitary adenoma)

Pituitary adenomas can cause hormonal hypersecretion and the cause of this woman's amenorrhoea is likely to be hyperprolactinaemia. Pressure on the optic chiasma can cause bitemporal hemianopia.

[Content Guide reference: Eye problems](#)
[Curriculum: 3.16 Care of People with Eye Problems](#)

34. Adverse drug reactions

A 67-year-old man with known long QT interval has a chest infection that requires antibiotic treatment.

According to the BNF, which SINGLE antibiotic is MOST important to AVOID in this situation? Select ONE option only.

- A. Amoxicillin
- B. Ciprofloxacin
- C. Clarithromycin
- D. Co-amoxiclav
- E. Doxycycline

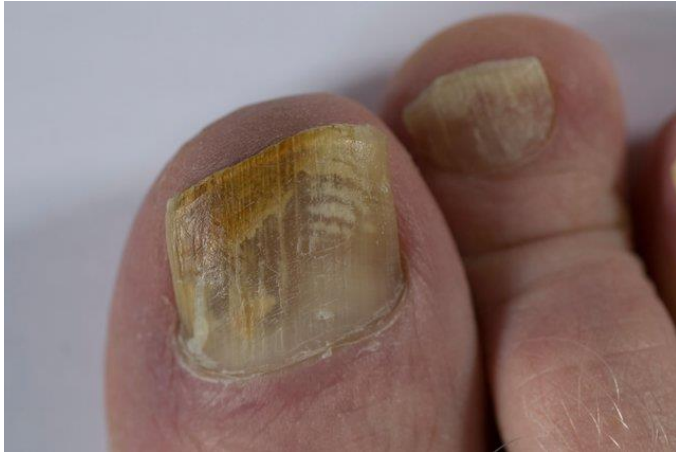Answer C. (Clarithromycin)

All macrolides, clarithromycin, azithromycin, erythromycin predispose to QT interval prolongation.

[Content Guide reference: Pharmaco-therapeutics](#)
[Curriculum: 2.2 Patient Safety and Quality of Care](#)

35. Toenail problem

A 53-year-old man complains of discoloured toenails which are causing discomfort. The appearance of the nails is as shown.



Which is the **SINGLE MOST** appropriate **INITIAL** treatment? Select **ONE** option only.

- A. Oral fluconazole
- B. Oral griseofulvin
- C. Oral terbinafine
- D. Topical clotrimazole
- E. Topical terbinafine

Answer C. (Oral terbinafine)

Terbinafine is the first-line oral agent for treating *Trichopython rubrum* nail infections. Fluconazole is less effective for dermatophyte infections but is sometimes used for yeast infections. Topical agents are not successful in any but the most superficial fungal nail infections.

[Content Guide reference: Skin problems](#)
[Curriculum: 3.21 Care of People with Skin Problems](#)

36. Sore throat

A 34-year-old woman has had a sore throat for two days. She has ulcerative colitis which is well controlled with maintenance oral mesalazine.

She has a mild fever of 37.8 °C and has pus on her tonsils.

Which is the SINGLE MOST appropriate INITIAL investigation? Select ONE option only.

- A. ASO titre
- B. FBC
- C. Liver function tests
- D. Throat swab
- E. Urine for culture

Answer B. (FBC)

All aminosalicylates can cause rare but serious blood disorders, including agranulocytosis, aplastic anaemia, leukopenia, methaemoglobinaemia, neutropenia, and thrombocytopenia.

Patients should be warned to report fever, sore throat or abnormal bleeding in order to ensure an urgent blood count is performed.

[Content Guide reference: Haematology problems](#)
[Curriculum: 3.3 Care of Acutely Ill People](#)

37. Postnatal depression

Which is the **SINGLE MOST** appropriate antidepressant to prescribe to a breastfeeding mother with postnatal depression? Select **ONE** option only.

- A. Duloxetine
- B. Escitalopram
- C. Fluoxetine
- D. Mirtazapine
- E. Sertraline

Answer E. (Sertraline)

Antidepressants can be used by breastfeeding women if drug therapy benefits are thought to outweigh the risks. Sertraline is thought to be the safest on the list given due to low expression in breast milk whereas the others are advised to be avoided.

[Content Guide reference: Mental health problems and Women's health](#)
[Curriculum: 3.10 Care of People with Mental Health Problems](#)

38. Cluster headaches

A 45-year-old man has cluster headaches which have failed to respond to sumatriptan. He has attended a specialist headache clinic for further advice.

According to current national guidance, which is the SINGLE MOST appropriate NEXT treatment for his acute episodes? Select ONE option only.

- A. Fentanyl patch
- B. GTN spray
- C. High flow oxygen
- D. Nasal nicotine
- E. Sublingual buprenorphine

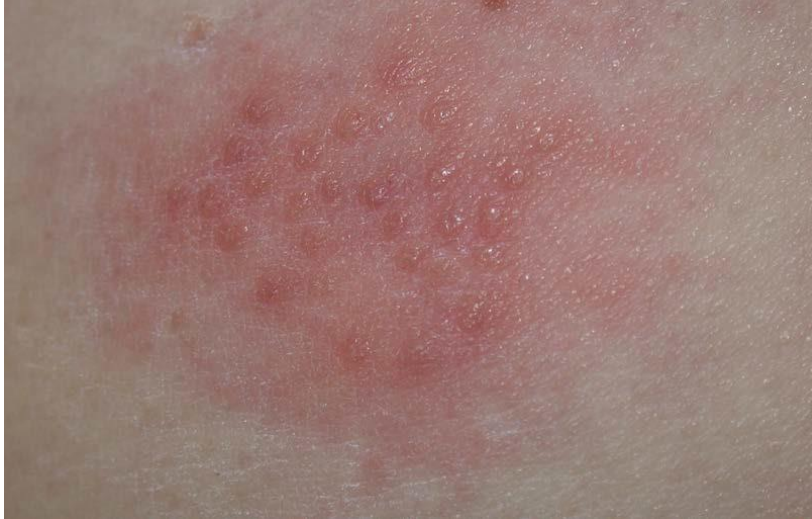Answer C. (High flow oxygen)

High flow oxygen is a specialist treatment for cluster headaches that do not respond to a triptan. It is important to be aware of what other options are available from secondary care. Opiates should be avoided for cluster headaches.

[Content Guide reference: Neurological problems](#)
[Curriculum: 3.18 Care of People with Neurological Problems](#)

39. Skin rash

A 34-year-old woman has had a rash on her buttock for the past two days. It is sore to touch and she has no rash elsewhere. She says this has happened on at least three previous occasions and the rash is always in the same place.



Which is the **SINGLE MOST** likely diagnosis? Select **ONE** option only.

- A. Coxsackie virus infection
- B. Dermatitis herpetiformis
- C. Herpes simplex
- D. Pompholyx
- E. Shingles

Answer C. (Herpes simplex)

This recurrent vesicular rash is most likely due to herpes simplex, which can occur anywhere on the body, although is most common on the lips and genitals.

[Content Guide reference: Infectious diseases and Skin Problems](#)
[Curriculum: 3.21 Care of People with Skin Problems](#)

Limping child

- A. Chondromalacia patellae
- B. Developmental dysplasia of the hip
- C. Juvenile arthritis
- D. Non-accidental injury
- E. Osgood-Schlatter's disease
- F. Osteosarcoma
- G. Perthes disease
- H. Septic arthritis
- I. Slipped upper femoral epiphysis
- J. Transient synovitis

For each child described, select the SINGLE MOST likely diagnosis from the list of options.

40. A 12-year-old boy has had right thigh and knee pain for about four weeks and has now started limping. He can weight bear, has normal knee movements but has reduced internal rotation of his right hip.

His BMI is 28 kg/m². His temperature is 37.1 °C.

Answer I. (Slipped upper femoral epiphysis)

Obesity is a risk factor for slipped upper femoral epiphysis, which affects pre-teens and teens and often presents with referred pain to the thigh and knee. Examination usually reveals reduced internal rotation due to pain. This is a commonly missed condition and is important for GPs to recognise.

[Content Guide reference: Children and young people and Musculo-skeletal problems including trauma](#)

[Curriculum: 3.4 Care of Children and Young people](#)

41. A five-year-old girl had chickenpox two weeks ago. She is now limping and complaining of pain in her left leg. Her temperature is 37.4 °C and she has a full range of movement of the left knee and hip.

Answer J. (Transient synovitis)

Transient synovitis is a common cause of limp in children aged four to eight years, typically following a viral infection.

[Content Guide reference: Children and young people and Musculo-skeletal problems including trauma](#)

[Curriculum: 3.4 Care of Children and Young people](#)

42. Atrial fibrillation

A 62-year-old gardener has heart failure due to left ventricular dysfunction. He is seen for annual routine review.

His pulse is 96/min and irregular and his blood pressure is 135/72.

An ECG confirms a new diagnosis of atrial fibrillation.

Which is the SINGLE MOST appropriate INITIAL medication, if any, to control his heart RATE? Select ONE option only.

- A. Bisoprolol
- B. Digoxin
- C. Sotalol
- D. Verapamil
- E. No rate-control treatment required

Answer A. (Bisoprolol)

Rate-controlling treatment should be offered first-line aiming for a resting heart rate of 60-80 beats per minute. A beta blocker (with the exception of sotalol) or rate-limiting calcium channel blocker should be offered. However, the latter is contraindicated in heart failure, making bisoprolol a more appropriate choice for this patient. Digoxin should only be considered in sedentary people.

For a topic such as atrial fibrillation, there is a wide range of possible questions such as anti-coagulation and rhythm control, but this question asks specifically about INITIAL management of rate control. It is important to read the question carefully and focus on the question being asked.

NICE CG180 Atrial Fibrillation: Management

[Content Guide reference: Cardiovascular problems](#)
[Curriculum: 3.12 Cardiovascular Health](#)

43. Constipation

A 92-year-old woman who lives alone and cares for herself, has long-standing constipation. She has no rectal bleeding or pain, her weight is steady, abdominal and rectal examinations are normal and she is otherwise well.

Which is the SINGLE MOST likely cause of her constipation? Select ONE option only.

- A. Alzheimer's disease
- B. Carcinoma of the colon
- C. Diverticular disease
- D. Hypothyroidism
- E. Poor fibre intake

Answer E. (Poor fibre intake)

The most likely cause of this patient's constipation is dietary, and there are no indicators of more serious disease in her history and examination.

[Content Guide reference: Digestive problems including nutrition](#)
[Curriculum: 3.5 Care of Older Adults](#)

44. Respiratory symptoms

A 34-year-old man has a persistent cough and wheeze following a viral infection four weeks ago. He is a non-smoker.

His peak expiratory flow rate is 500 L/min (expected range 580-620 L/min). A diagnosis of asthma is being questioned.

According to SIGN/BTS guidelines (2016), which is the SINGLE MOST appropriate inhaled medication to trial? Select ONE option only.

- A. Beclomethasone
- B. Ipratropium
- C. Salbutamol
- D. Salmeterol and fluticasone
- E. Tiotropium

Answer A. (Beclomethasone)

This man has typical symptoms of asthma (wheeze, exacerbation with viral illnesses). In people with a high probability of asthma, current updated SIGN/BTS guidelines (2016) now suggest initiating inhaled corticosteroids for six weeks as a first step, with a good response confirming the diagnosis.

[Content Guide reference: Respiratory problems](#)
[Curriculum: 3.19 Respiratory Health](#)

45. Nocturia

A 67-year-old man has nocturia and post-micturition dribbling which is interfering with his sleep. He has an International Prostate Symptom Score of 9, which is in the moderate range (8 to 19).

Clinical examination and investigations are in keeping with benign prostatic hyperplasia with a minor degree of prostate enlargement.

Which is the SINGLE MOST appropriate INITIAL treatment? Select ONE option only.

- A. Duloxetine
- B. Finasteride
- C. Oxybutynin
- D. Solifenacin
- E. Tamsulosin

Answer E. (Tamsulosin)

NICE guidance recommends that if a man has moderate-to-severe voiding symptoms (which would correspond to an International Prostate Symptom Score of 8 or more), the first-line treatment is an alpha-blocker (alfuzosin, doxazosin, tamsulosin, or terazosin).

If the prostate is significantly enlarged and likely to progress to retention, then finasteride should be considered either alone or in combination.

[Content Guide reference: Men's health](#)
[Curriculum: 3.07 Men's Health](#)

46. Chronic kidney disease (CKD)

A 64-year-old woman with CKD Stage 3 and hypertension has an annual review. Her mean of several clinic and home BP measurements is 143/84. She is currently taking amlodipine 5 mg and atorvastatin 20 mg daily.

Her renal function is stable with an eGFR of 54 ml/min and her urinary albumin:creatinine ratio is 45 mg/mmol (normal range < 3 mg/mmol).

**Which is the SINGLE MOST appropriate ADDITIONAL drug treatment, if any?
Select ONE option only.**

- A. Aspirin
- B. Clopidogrel
- C. Indapamide
- D. No additional drug therapy indicated
- E. Ramipril

Answer E. (Ramipril)

NICE suggest a low-cost renin-angiotensin system antagonist for people with CKD, hypertension and an ACR > 30 mg/mmol as well as suggesting a target BP of lower than 140/90.

[Content Guide reference: Renal problems](#)
[Curriculum: 3.17 Care of People with Metabolic Problems](#)

47. Sickle cell disease

A couple have just undergone screening for sickle cell disease in pregnancy and both are found to be carriers.

What is the chance of their child having sickle cell disease? Select ONE option only.

- A. 0%
- B. 25%
- C. 50%
- D. 75%
- E. 100%

Answer B. (25%)

Sickle cell disease is carried on an autosomal recessive gene so if both parents are carriers, there is a 25% chance the child will have the disease, a 50% chance of being a carrier and 25% chance of not being affected.

[Content Guide reference: Genetics](#)

[Curriculum: 3.2 Genetics in Primary Care](#)

48. Anticoagulant therapy

An 84-year-old man has just undergone mitral valve replacement with a mechanical valve.

Which is the SINGLE MOST appropriate anticoagulant? Select ONE option only.

- A. Apixaban
- B. Aspirin
- C. Clopidogrel
- D. Dabigatran
- E. Warfarin

Answer E. (Warfarin)

A mechanical valve replacement requires lifelong anticoagulation with warfarin and the novel oral anticoagulants are not licensed for this indication.

[Content Guide reference: Haematology problems and Cardiovascular problems](#)
[Curriculum: 3.12 Cardiovascular Health](#)

49. Psychiatric medication

A 45-year-old woman is admitted to hospital with an acute depressive episode. She is started on medication. She suddenly develops shivering, sweating, diarrhoea and confusion.

Which is the SINGLE MOST likely drug to have been started? Select ONE option only.

- A. Fluoxetine
- B. Lithium
- C. Mirtazapine
- D. Trazodone
- E. Valproate

Answer A. (Fluoxetine)

This is serotonin syndrome. Fluoxetine is the only SSRI on the list. Serotonin syndrome is a severe illness which tends to develop over hours and requires cessation of the causative medication plus supportive care which may include admission to hospital for fluids.

Features of serotonin syndrome include confusion, delirium, shivering, sweating, changes in blood pressure and myoclonus.

[Content Guide reference: Mental health problems](#)

[Curriculum: 3.10 Care of People with Mental Health Problems](#)

50. End-of-life care

According to the current BNF, which is the **SINGLE MOST** appropriate anti-emetic to use in a syringe driver with diamorphine? Select **ONE** option only.

- A. Cyclizine
- B. Domperidone
- C. Glycopyrronium bromide
- D. Levomepromazine
- E. Ondansetron

Answer D. (Levomepromazine)

Either haloperidol or levomepromazine can be used as an anti-emetic in a subcutaneous infusion. Cyclizine can precipitate with higher doses of diamorphine or other drugs.

[Content Guide reference: Pharmaco-therapeutics](#)

[Curriculum: 3.9 End-of-life Care](#)